Intelligenza artificiale

per le indicazioni terapeutiche

Vincenzo Valentini

Gemelli 1964 2024
Fondazione Policlinico Universitario Agostino Gemelli IRCCS
Università Cattolica del Sacro Cuore

Ospedale Isola Tiberina
GEMELLI ISOLA

ART Advanced Radiation Therapy

Artificial Intelligence or Artificial IntelligenceS



IMAGES DRAWN BY AI (DALL-E)

Immagination and Fears by AIs



KNOWLEDGE-BASED CLINIC

Babylon AI Event video, 2019



SERVICE: AUTOMATED DATA COLLECTION

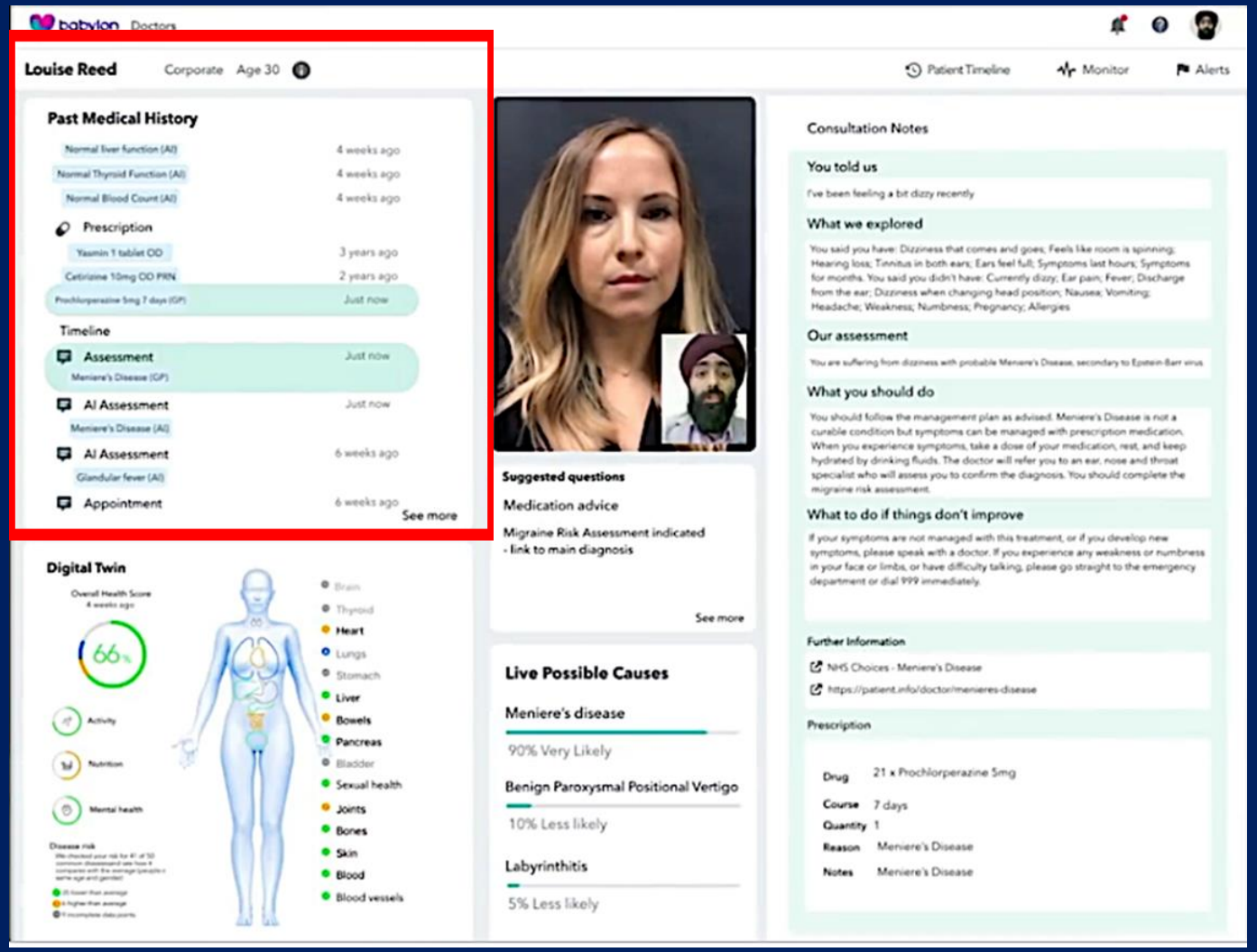

USE CASE: PATIENT JOURNEY (REMOTE MONITORING, MESSAGING)











DATI REAL-WORLD

ALERT

DATI CLINICI

MESSAGGISTICA

REPORT CONTATTI

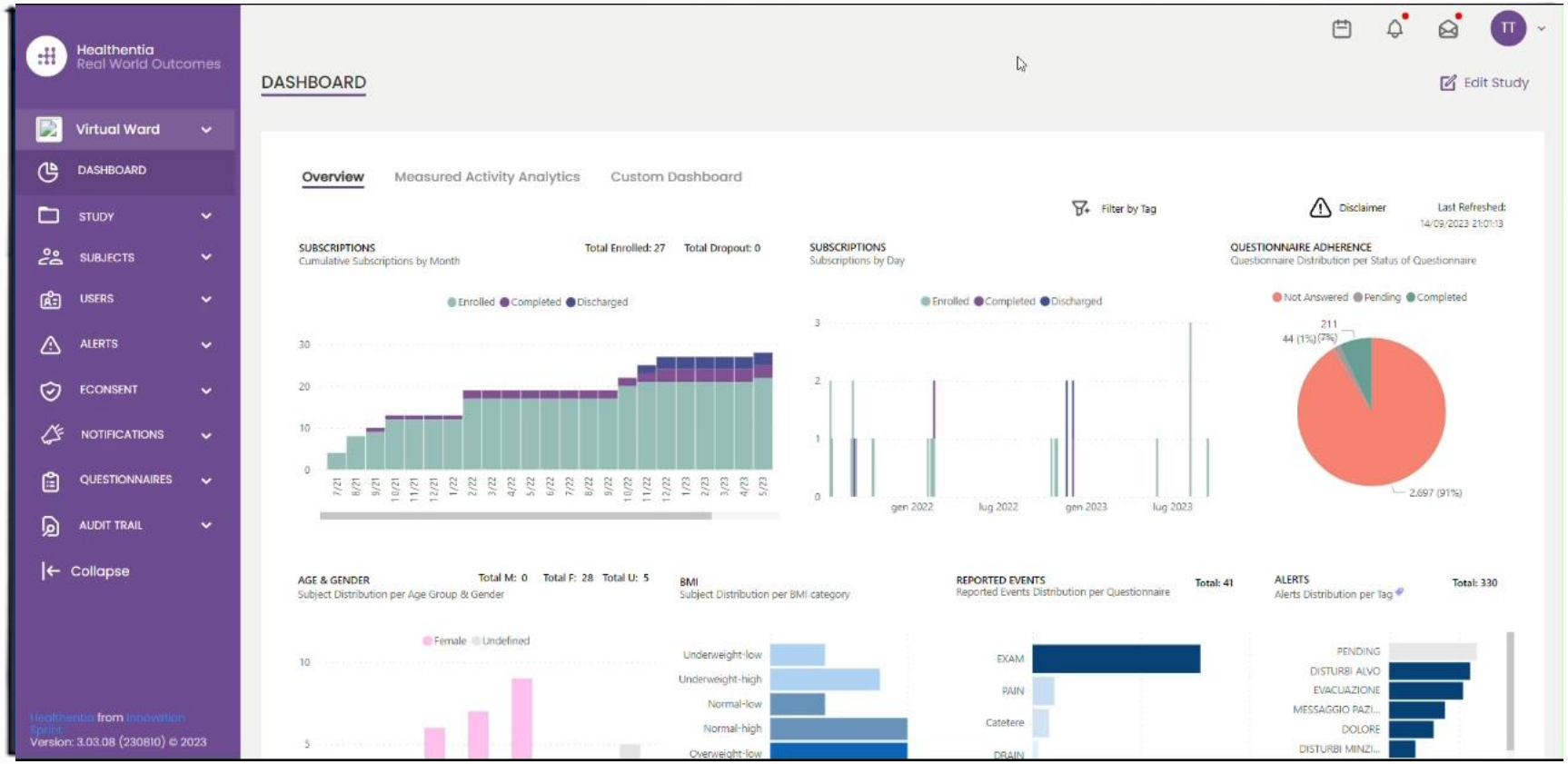

THE INNOVATION HYPE

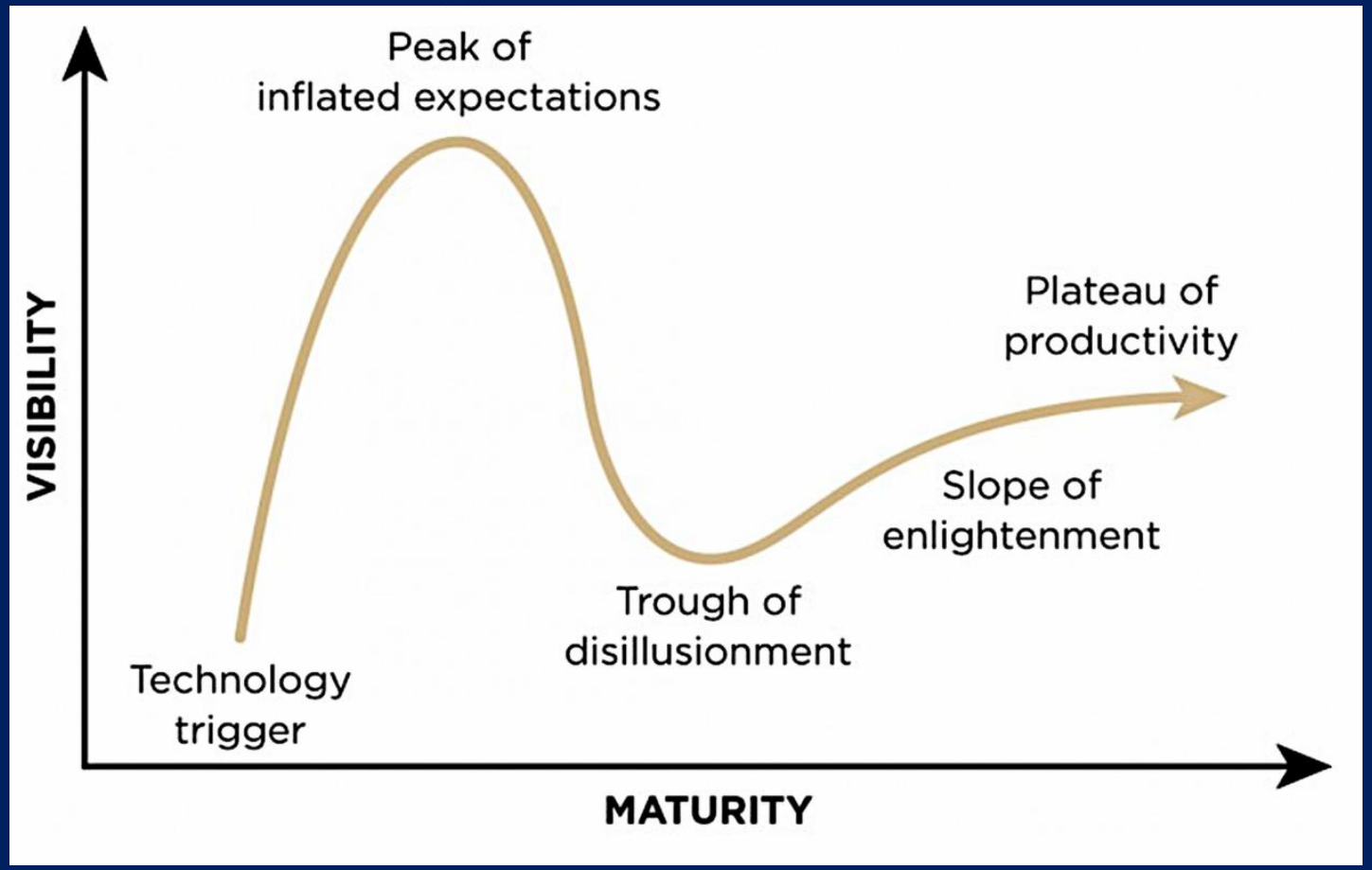

THE INNOVATION HYPE

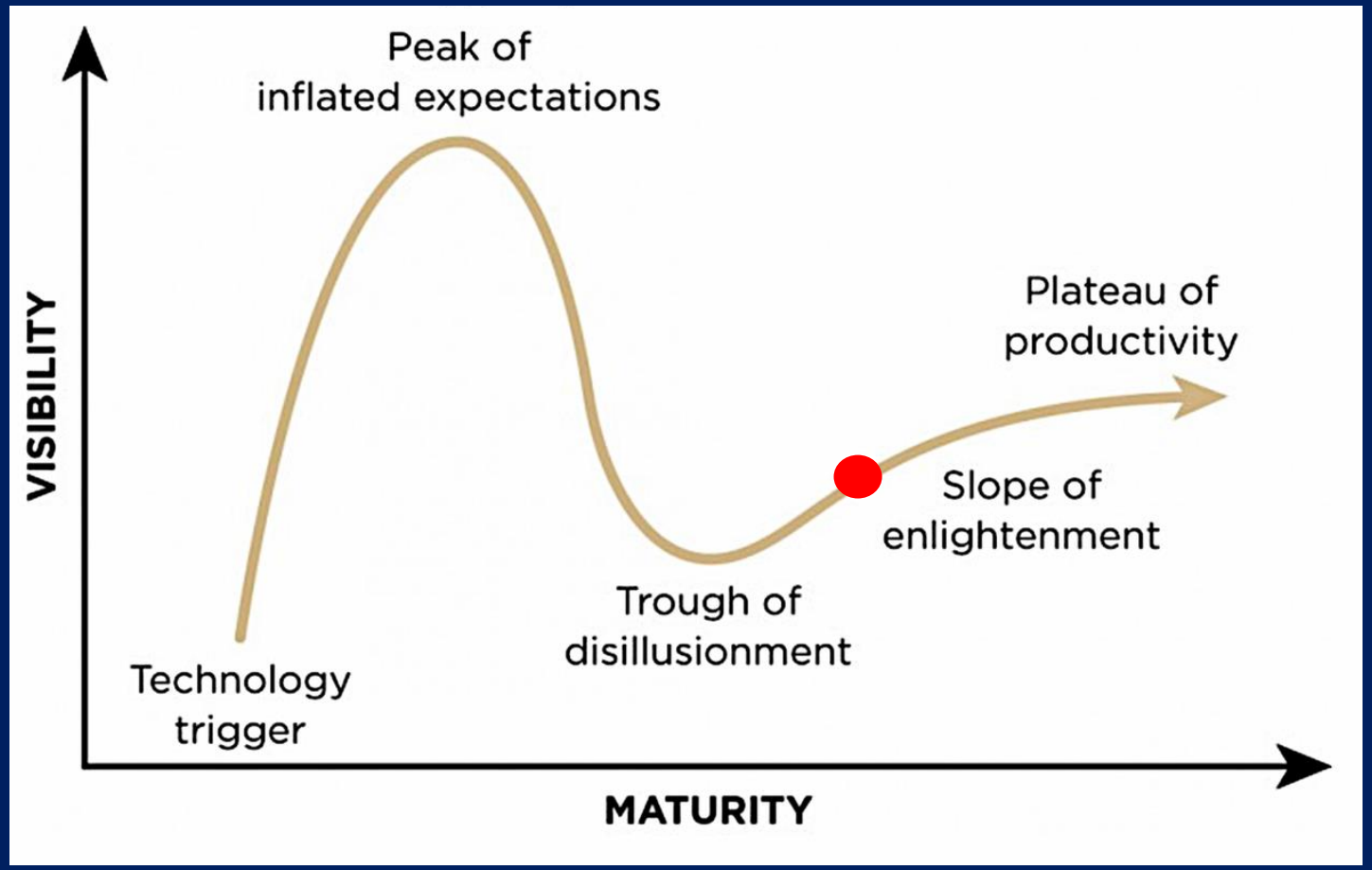

- Automated Data Collection

DYNAMIC DIAGNOSTIC MODELS

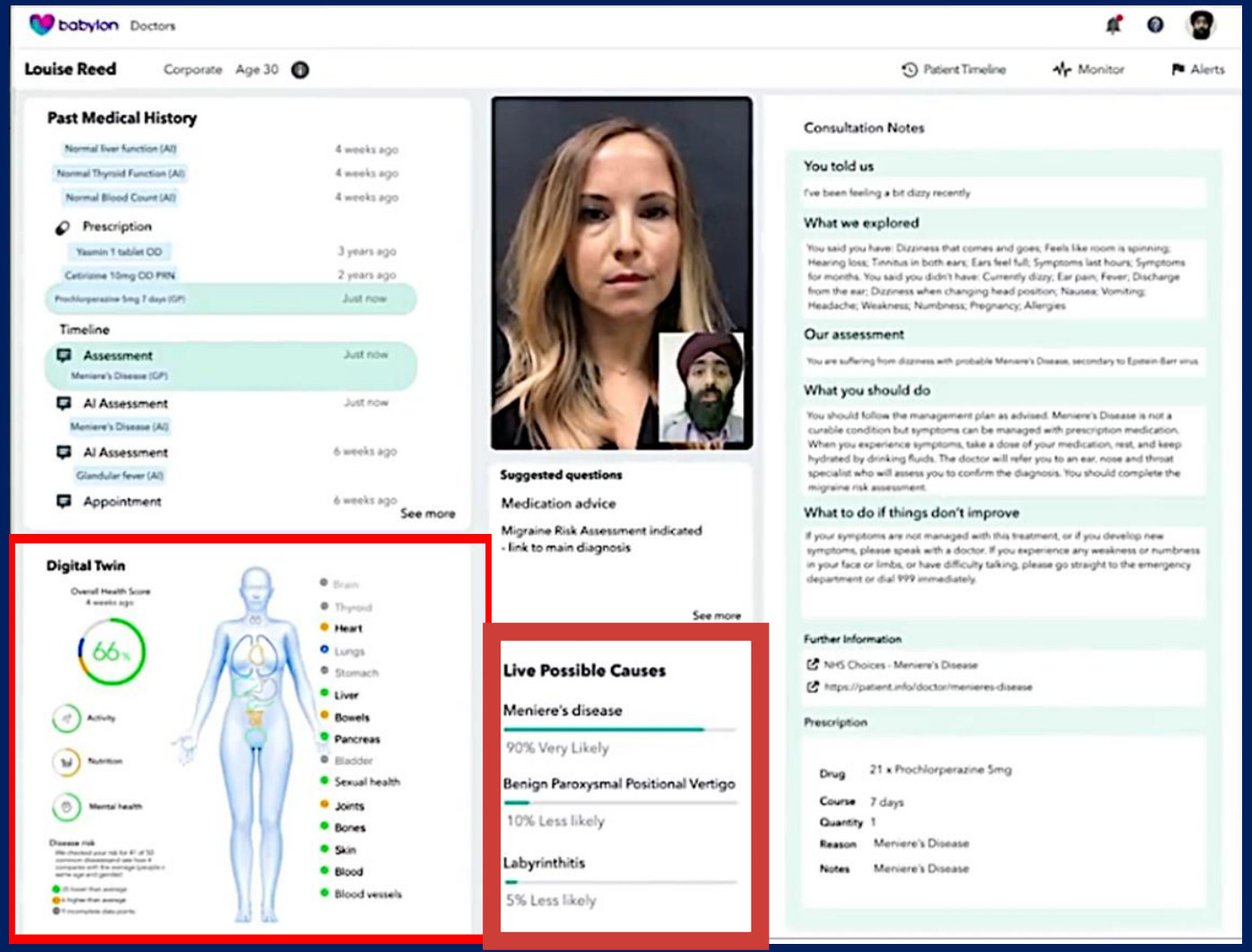

DYNAMIC DIAGNOSTIC MODELS: DIGITAL TWIN

RECTUM CANCER DATAMART & ANALYTICS DASHBOARD

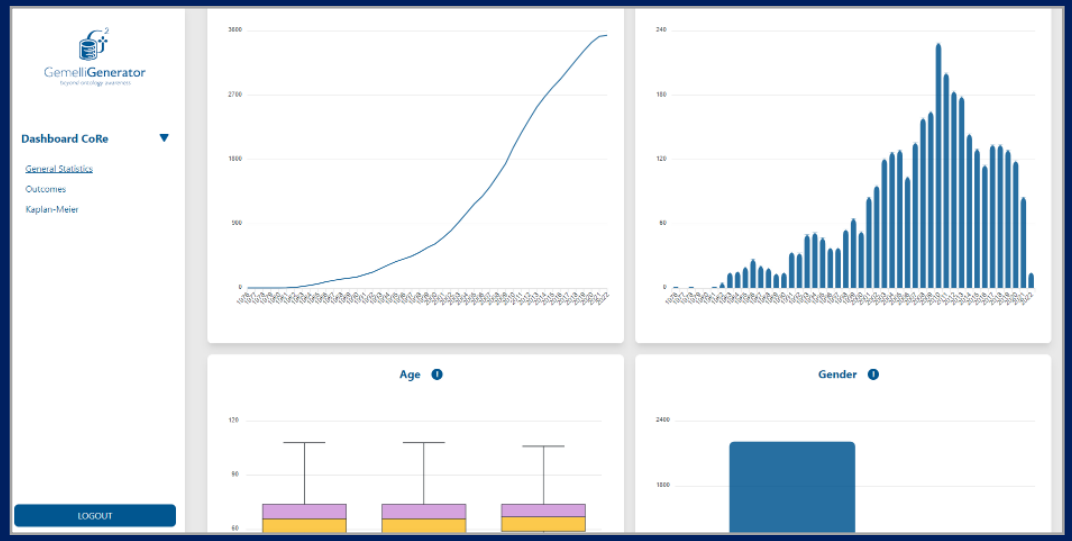

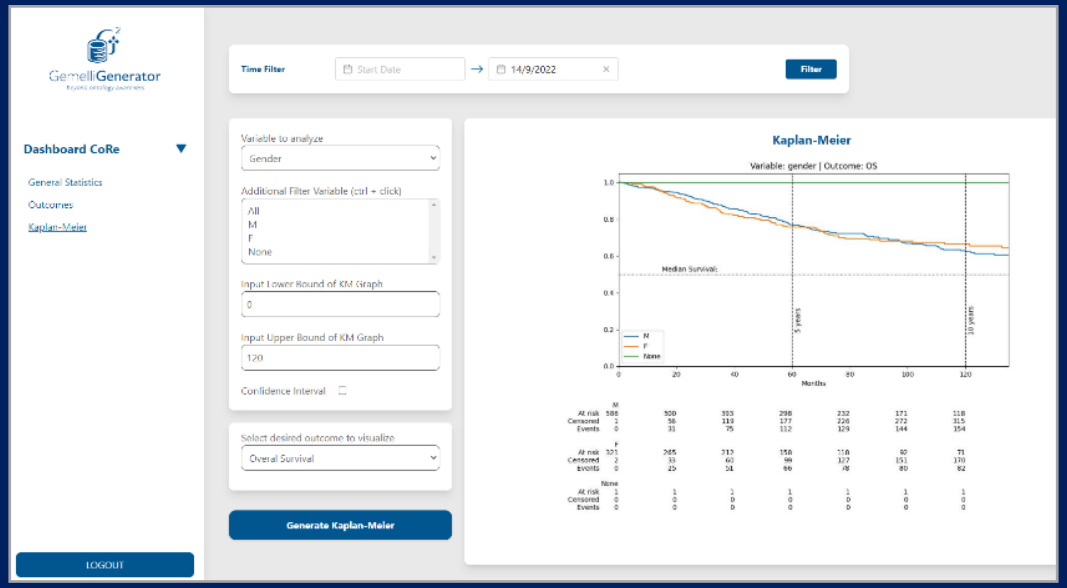

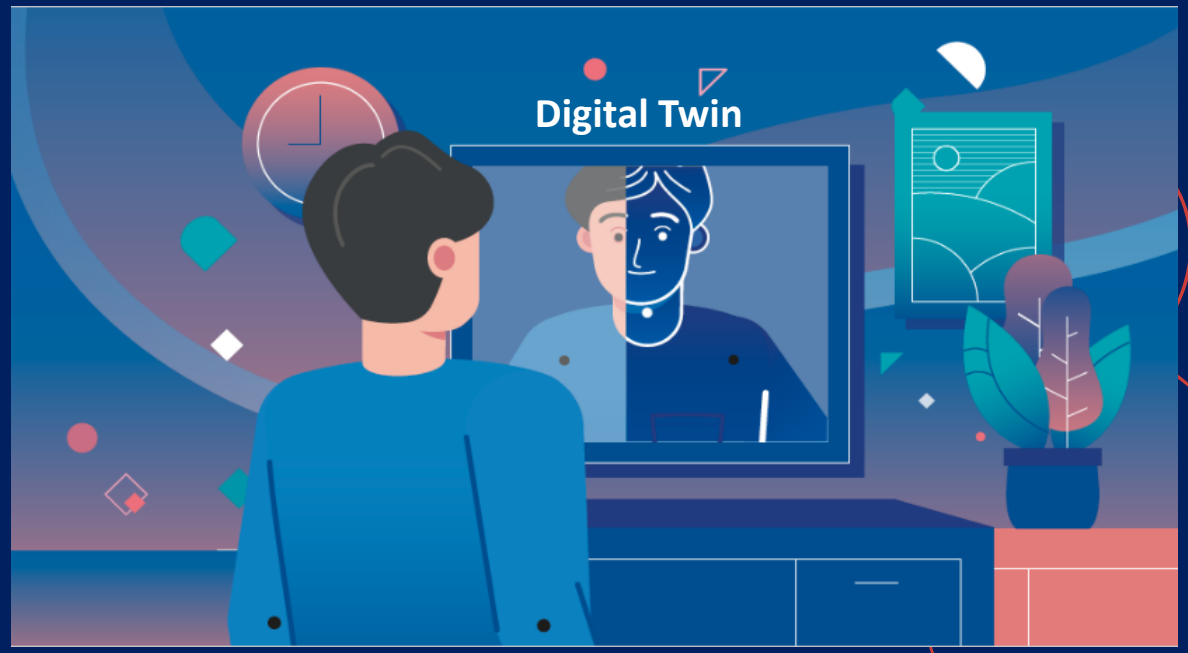

DYNAMIC DIAGNOSTIC MODELS: DIGITAL TWIN

SURGICAL COMPLICATIONS

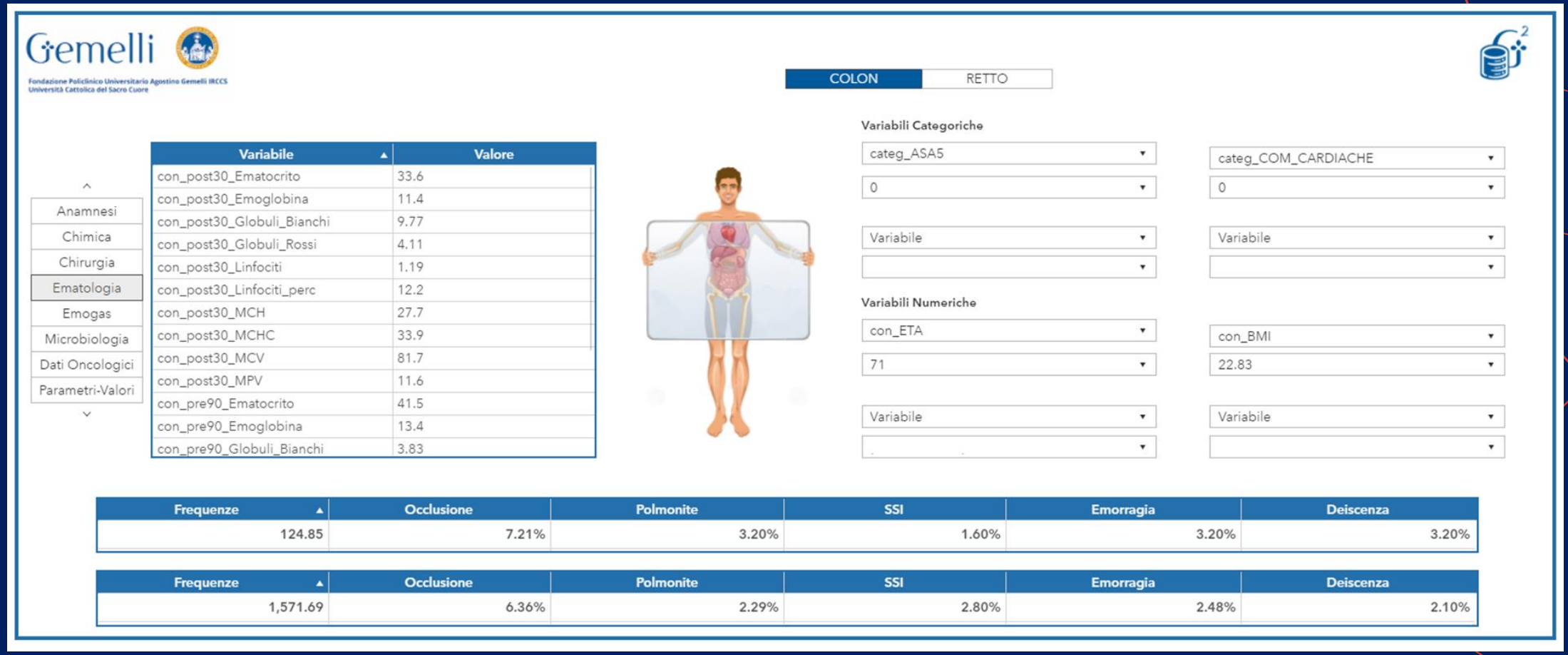

DYNAMIC DIAGNOSTIC MODELS: DEEP LEARNING

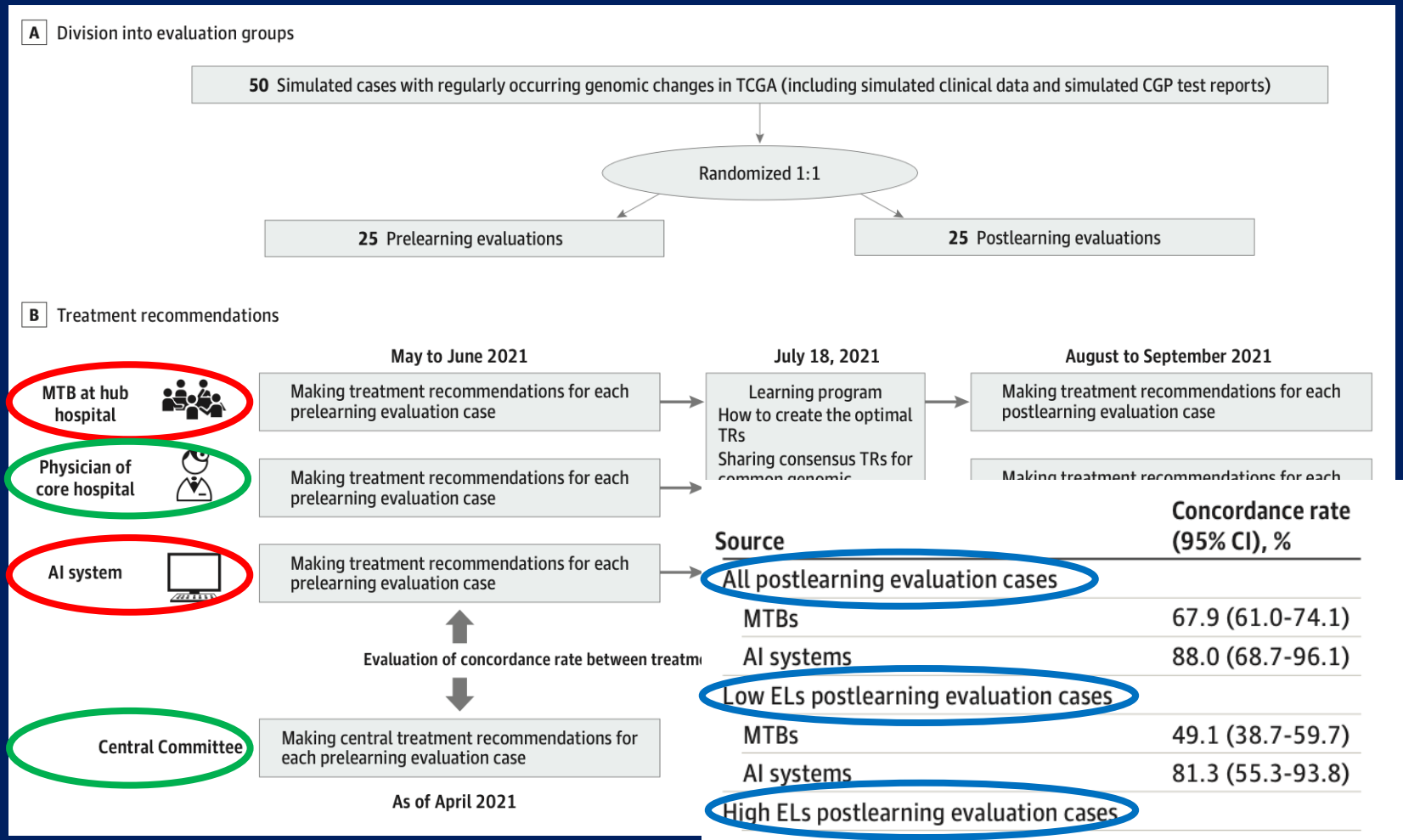

Source	Concordance rate (95% CI), %
All postlearning evaluation cases	
MTBs	67.9 (61.0-74.1)
AI systems	88.0 (68.7-96.1)
Low ELs postlearning evaluation cases	
MTBs	49.1 (38.7-59.7)
AI systems	81.3 (55.3-93.8)
High ELs postlearning evaluation cases	
MTBs	96.3 (92.0-98.3)
AI systems	100 (NA)

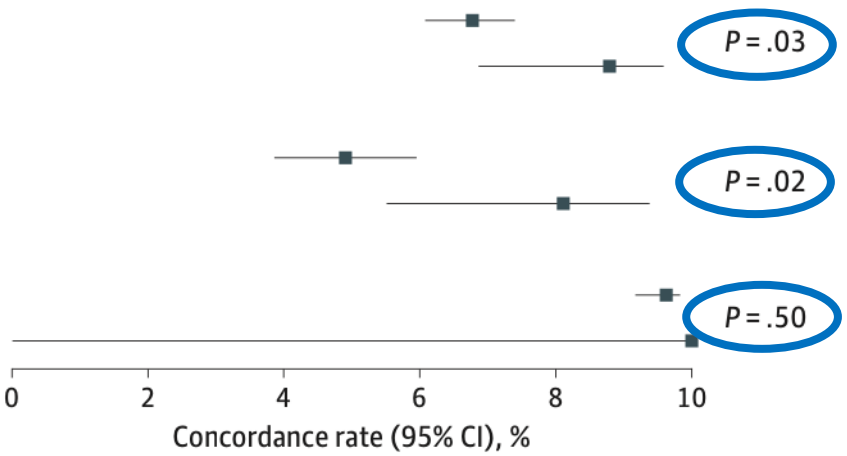

K Sunami – *JAMA* - 2023

DYNAMIC DIAGNOSTIC MODELS: FACIAL PREDICTION

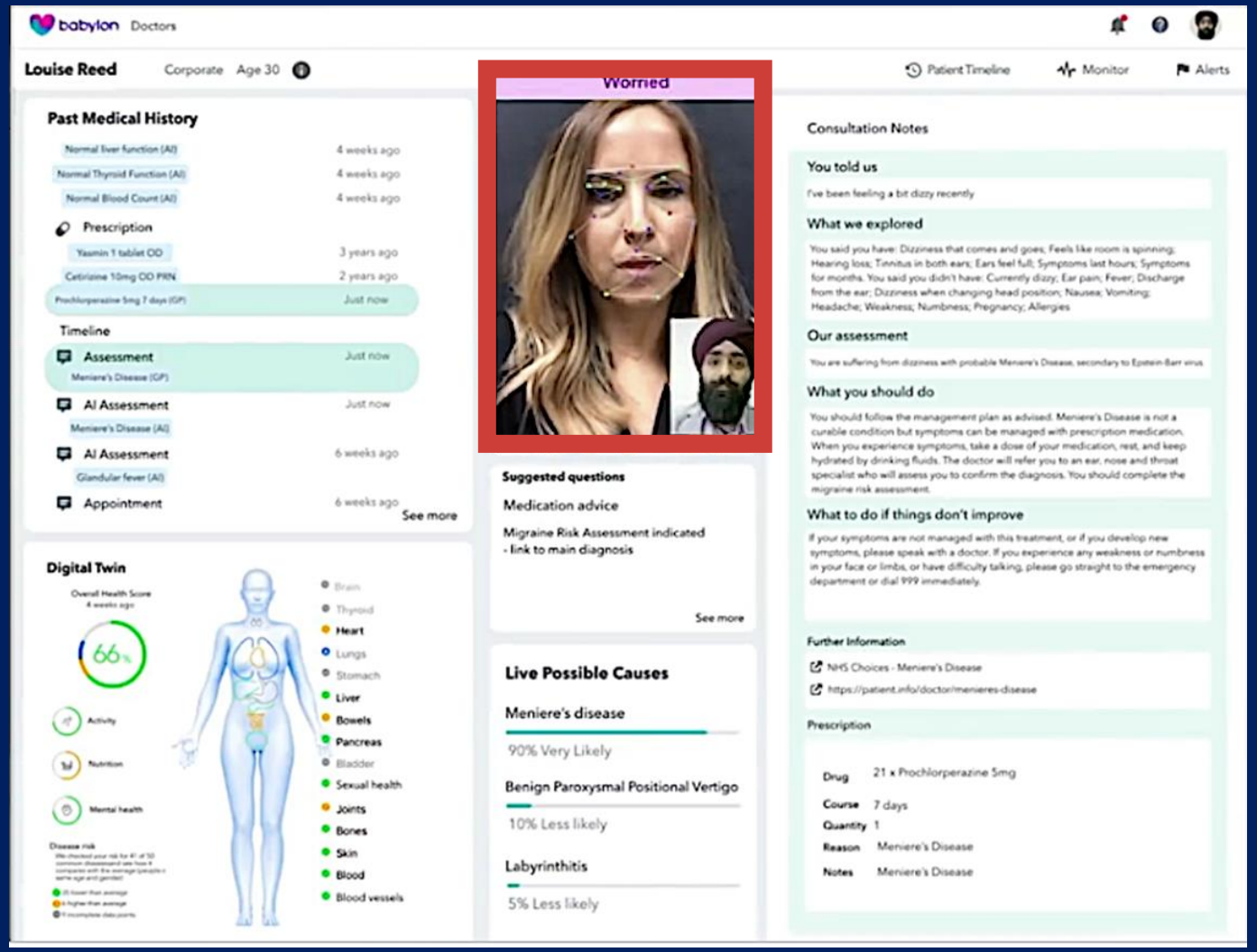

DYNAMIC DIAGNOSTIC MODELS: FACIAL PREDICTION

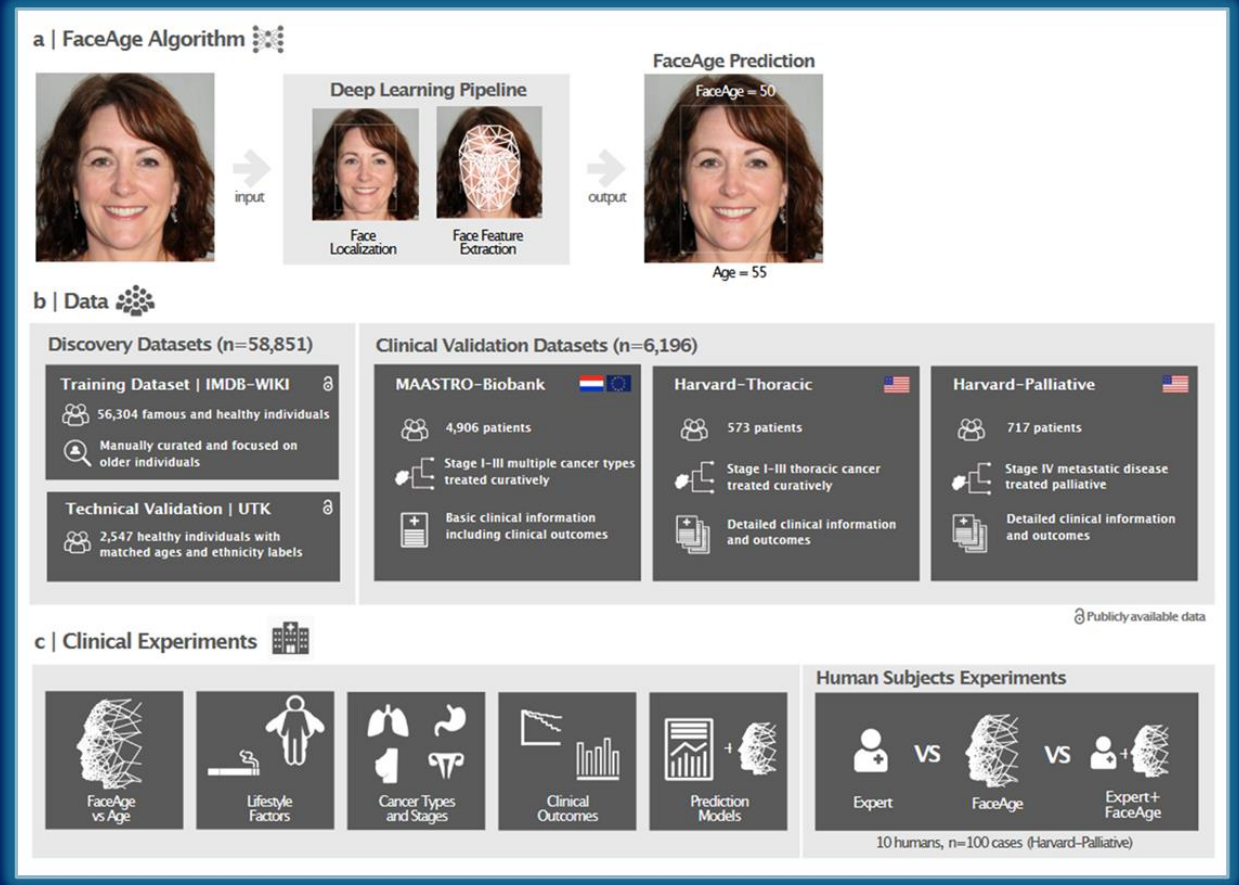

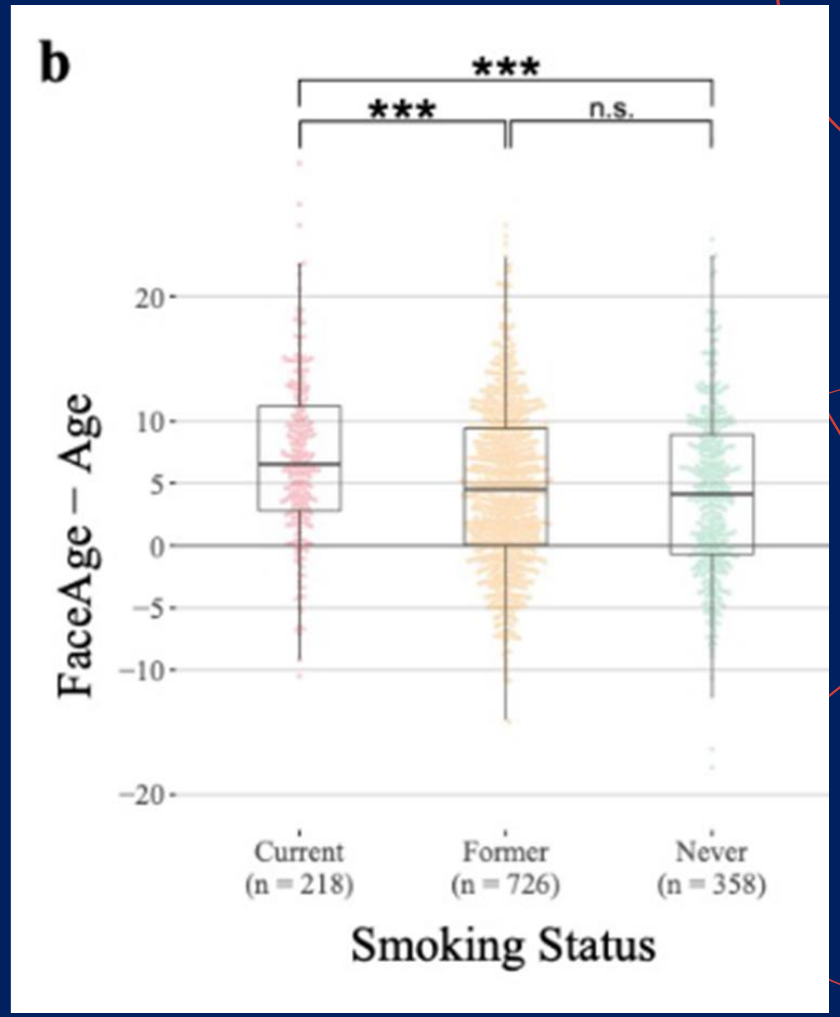

ZALAY ET AL. MEDRXIV. 2023 SEP 12;2023.09.12.23295132

THE INNOVATION HYPE

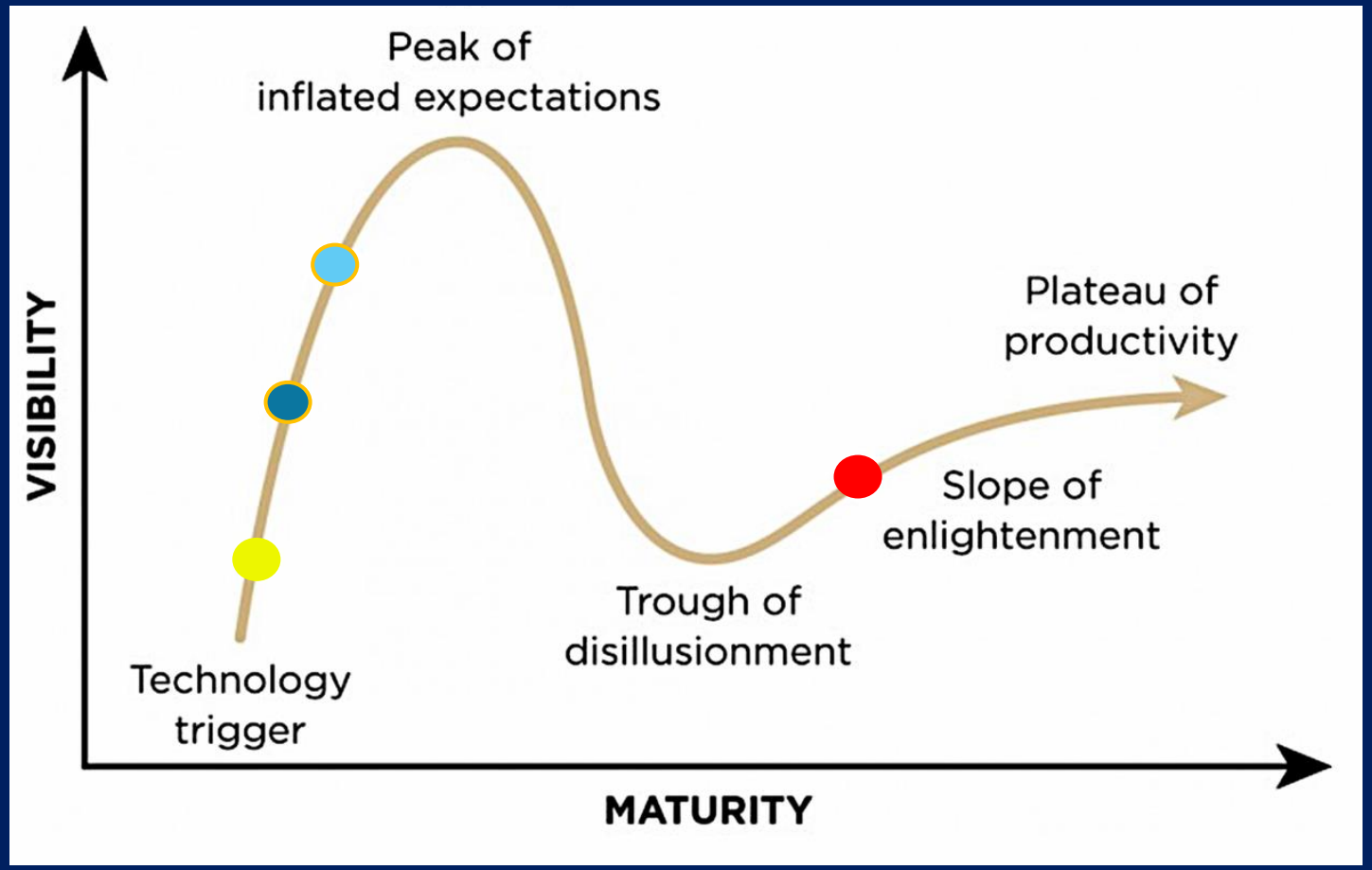

- Automated Data Collection
- DDM: Digital Twin
- DDM: Deep Learning
- DDM: Facial recognition

SERVICE: NATURAL LANGUAGE MODELS

CONVERSATIONAL AGENTS: CHATBOT

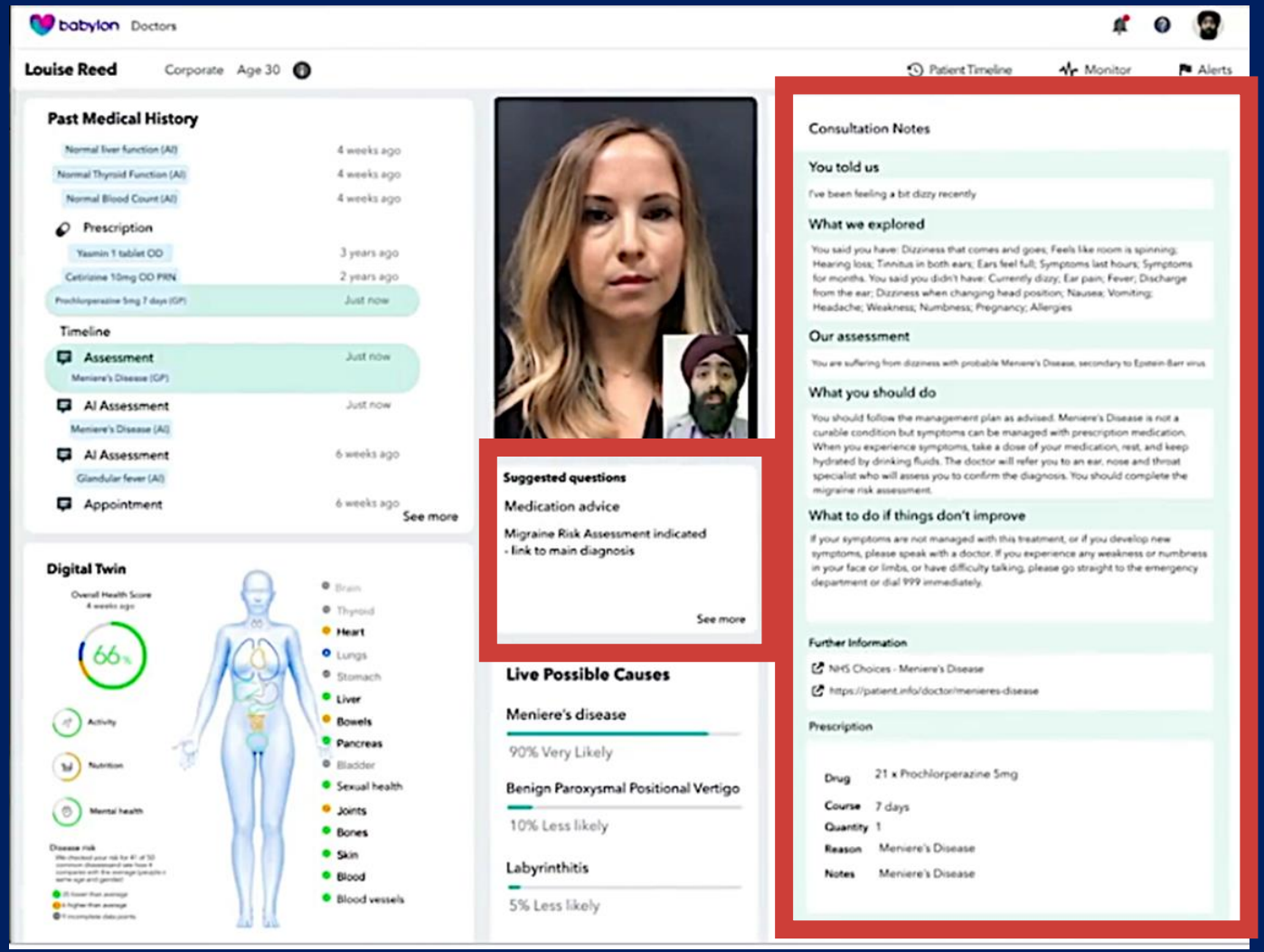



SERVICE: NATURAL LANGUAGE MODELS

USE CASE: MIXOMA



Gemelli

Fondazione Policlinico Universitario A. Gemelli
Università Cattolica del Sacro Cuore

Sede Legale F.Vito, 1 - 00168 Roma
Sede operativa L.go A. Gemelli, 8 - 00168 Roma
Codice Fiscale e P.IVA 13109681000
Tel. +39 0630151

Radiodiagnostica

Sospetto mixoma atriale Richiesto da:DE BENEDETTO FABIO

Referto — Data Esame 11/10/2023

RM CUORE (S/C MDC)

Tecnica: scanner 1.5 sequenze cineRM SSFP, T2-BB, di delayed enhancement (DE) e T1 e T2 mapping, secondo piani multipli prima e dopo somministrazione di mdc paramagnetico (0.1ml/kg, Gadobutrolo).

Descrizione:
In sede atriale SN si conferma la presenza di una formazione solida delle dimensioni massime di 28x20mm (sul piano 4-camere) che mostra ampio contatto con il SIA, caudalmente alla fossa ovale e con estensione sino in corrispondenza dell'inserzione sulla annulus del lembo anteriore mitralico, tale formazione appare altamente mobile, fluttuando in maniera sincrona al lembo anteriore valvolare mitralico (LAM) - con cui giunge in alcuni punti a contatto - e con parziale superamento dell'annulus valvolare in fase diastolica. La suddetta formazione presenta margini lobulati, segnale isointenso in T1, iperintenso in T2-BB e lieve ed eccentrica impregnazione contrastografica, maggiore sul versante del SIA. Il reperto è sospetto per mixoma.
Ventricolo SN di normali volumi (VTDi = 67ml/m2; VTSi= 29ml/m2) e conservato diametro telediastolico basale (46mm). Incremento asimmetrico dello spessore delle pareti ventricolari di SN, a maggiore espressione settale medio-basale (DTD SIV anteriore medio-basale: 13.5mm); regolare lo spessore telediastolico della parete basale postero-laterale (9mm).
Regolare la massa del miocardio compatto ventricolare SN (142gr; 69gr/m2).
Ventricolo DX di normali volumi (VTDi = m65l/m2; VTSi= 31ml/m2) e diametro telediastolico della camera di afflusso (44mm) ed efflusso (32mm).
Lo studio cine-RM documenta:
- acinesia di parte della parete antero
- ipocinesia della parete antero-latera
ventricolare.
Regolare la funzione sistolica globale
Regolare la funzione sistolica globale
Non significativi vizi valvolari.
Nelle immagini T2w si documenta ede
medio-ventricolare e, focalmente, dell
Nelle immagini di delayed enhanceme
antero-laterale e infero-laterale medio
tenue diffusa iperintensità subendocard
antero-laterale e inferiore medio-ventr
con alterazioni ischemiche.
Non evidenza di formazioni trombotich
Nei limiti i volumi atriali.
Non significativi vizi valvolari.
Normale lo spessore del pericardio.

Conclusioni:
- Formazione solida atriale SN in corr

"Referto firmato digitalmente ai sensi della norme
del 08/12/2000, D.L.G. del 23/01/2002."

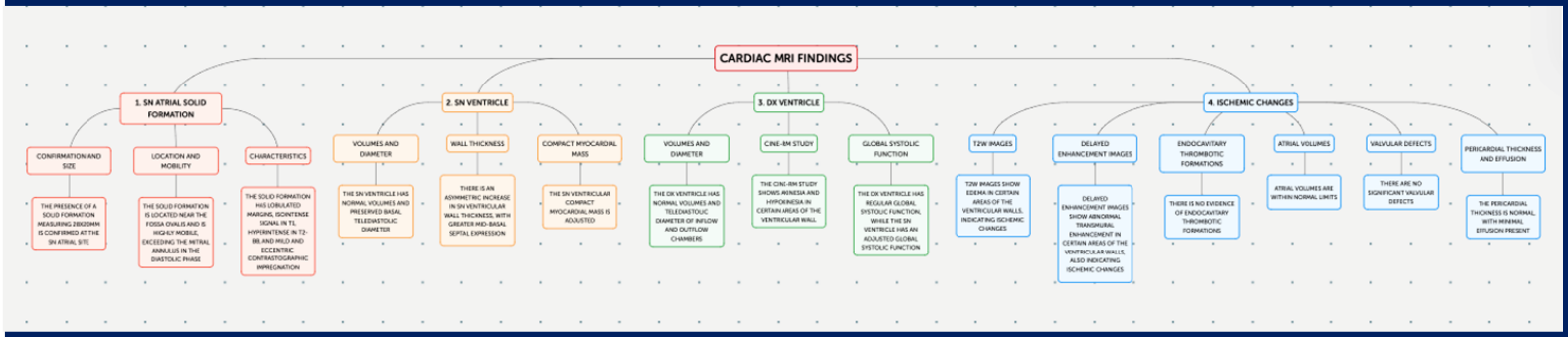

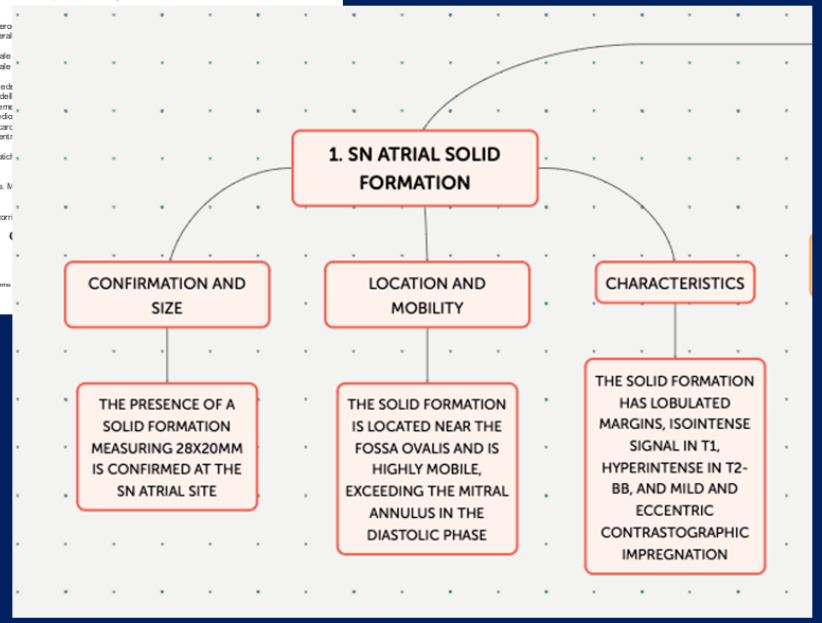

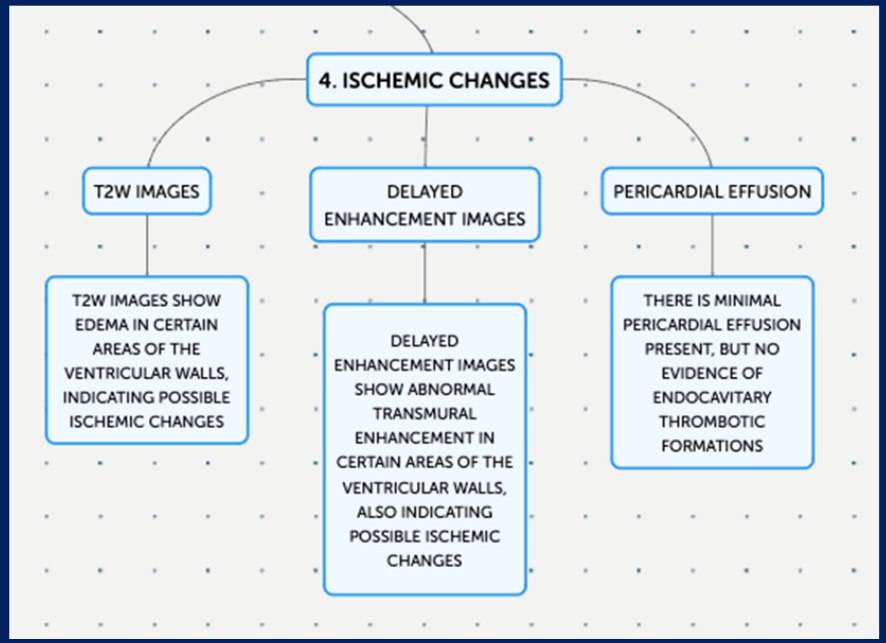



SERVICE: NATURAL LANGUAGE MODELS

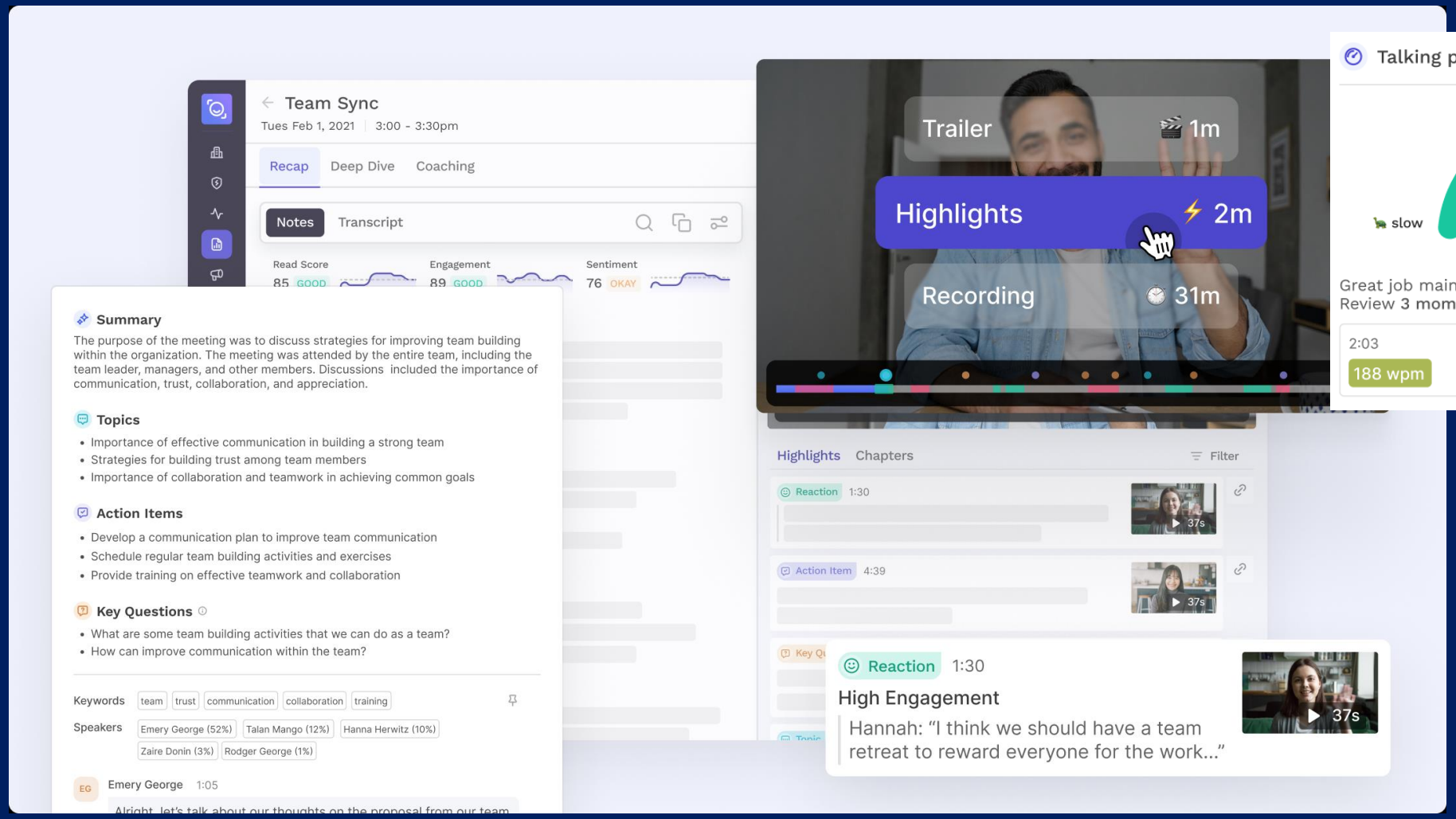

Read

THE INNOVATION HYPE

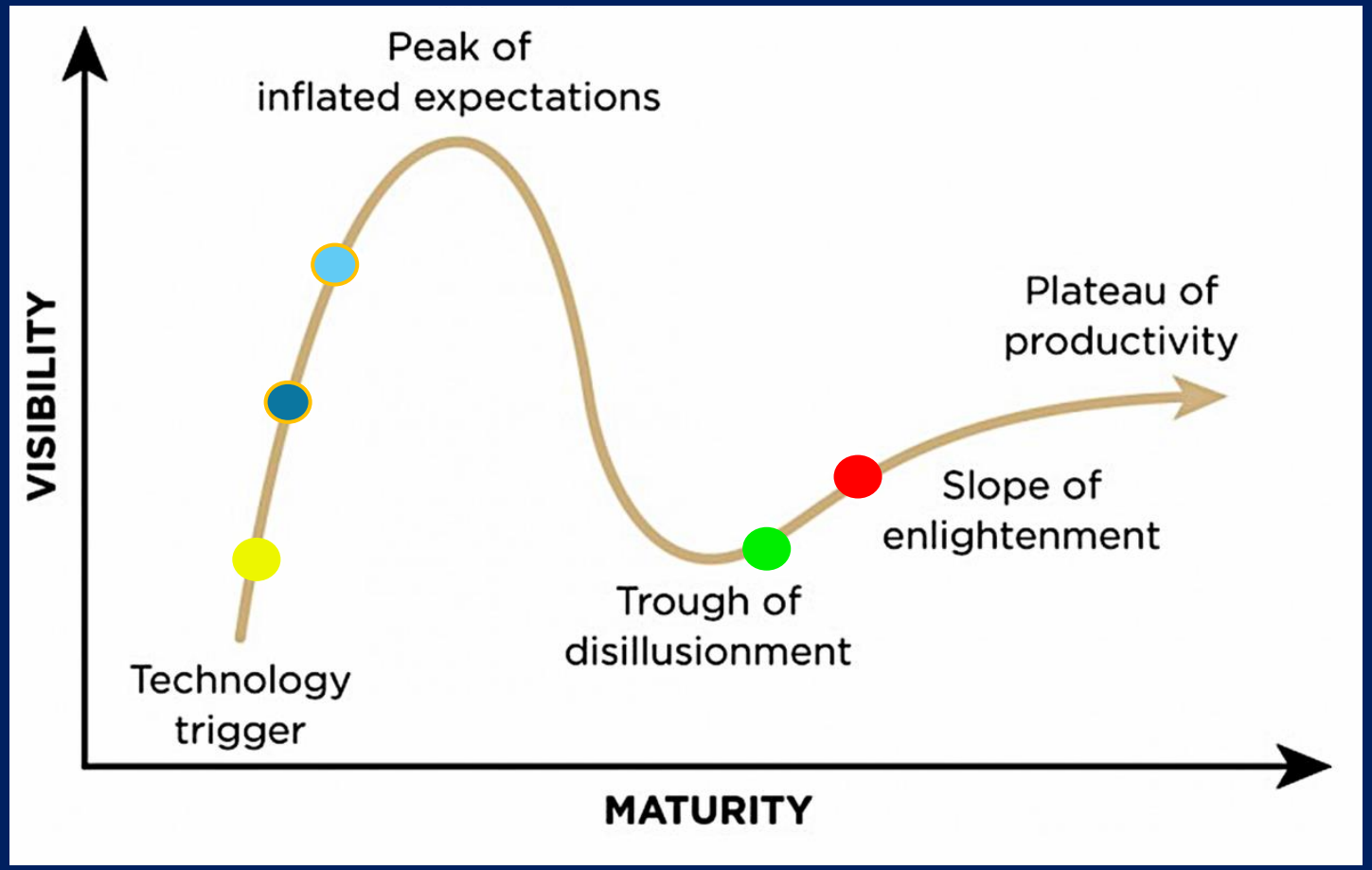

- Automated Data Collection
- DDM: Digital Twin
- DDM: Deep Learning
- DDM: Facial recognition
- Conversational agents

DOCTORS and AI

